



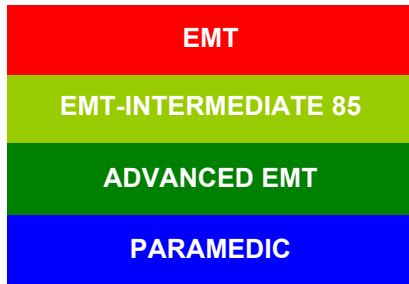
EMS System for Metropolitan Oklahoma City and Tulsa 2022 Medical Control Board Treatment Protocols



 EMS SECTION

Approved 9/8/21, Effective 1/17/22, replaces all prior versions

3H – WAVEFORM CAPNOGRAPHY ADULT & PEDIATRIC



Indications:

1. Medical General Assessment/General Supportive Care.
2. Trauma General Assessment/Trauma & Hypovolemic Shock Supportive Care.
3. Acute Dyspnea (Uncertain Etiology, Asthma, COPD, CHF, BRUE).
4. Confirmation of Endotracheal Airway Placement – EARLY USE INDICATED; SEE PROTOCOL 2J.
5. Mechanical Ventilation
6. Termination of Resuscitation; SEE PROTOCOL 4K
7. Neurologic Disorders/Altered Mental Status (Stroke, Seizure, Syncope).
8. Toxicologic/Poisonings (Altered Mental Status, Dyspnea).
9. Trauma (Head, Face, Neck, Chest Injuries).

Contraindications: None

Technique:

(Physio-Control LifePak® 12/15) to Monitor EtCO₂:

1. Make sure the monitor is ON.
2. Select the appropriate EtCO₂ accessory for the patient.
3. Open the CO₂ port door and insert the FilterLine® connector; turn connector clockwise until tight.
4. Verify that the CO₂ area is displayed. The EtCO₂ monitor performs the autozero routine as part of the initialization self-test.
5. Display CO₂ waveform in Channel 3 on the LifePak screen.
6. Connect the CO₂ FilterLine® set to the patient.
7. Confirm that the EtCO₂ value and waveform are displayed.



Note: Do not connect the FilterLine® set to the patient/ventilation system until the EtCO₂ monitor has completed its self-test and warm-up.



EMS System for Metropolitan Oklahoma City and Tulsa 2022 Medical Control Board Treatment Protocols



Approved 9/8/21, Effective 1/17/22, replaces all prior versions

PROTOCOL 3H: Waveform capnography – Adult & Pediatric, cont.

Critical Comment:

When CO₂ is **NOT** detected, four factors must be quickly assessed:

1. Loss of airway - apnea? esophageal endotracheal tube placement/migration? obstruction?
2. Circulatory collapse - cardiac arrest? massive pulmonary embolism? exsanguination?
3. Equipment failure - disconnected or malfunctioning bag-valve or ventilator?
4. Adjust EtCO₂ scale to 0-20 and print 6 second strip to verify waveform capnography.

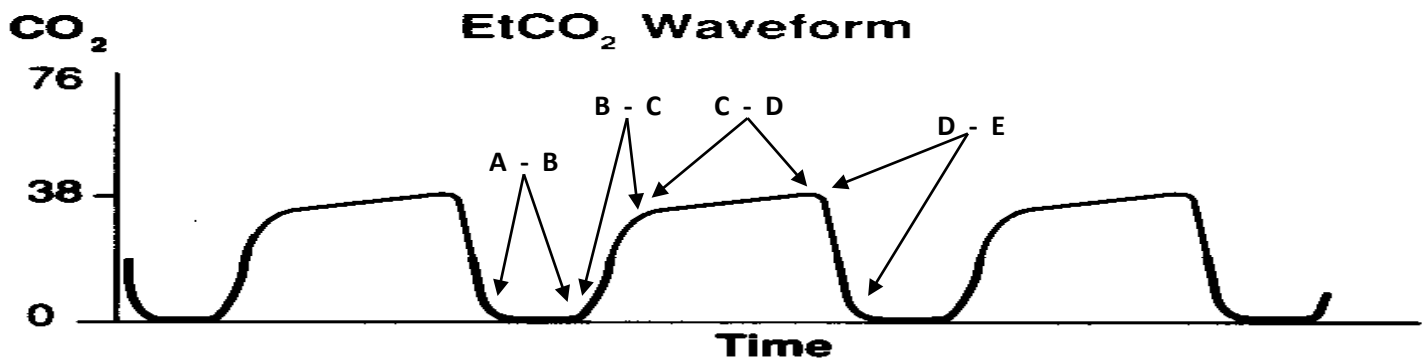
Interpreting Capnography:

The figure below shows a normal capnography waveform display. There are 4 phases of the waveform that require analysis. The flat **A – B** baseline segment (Respiratory Baseline) represents the beginning of exhalation of CO₂ – free gas that is contained in dead space from the conduction airways (trachea, bronchi). This value normally is zero. The **B – C** segment (Expiratory Upstroke), a sharp rise, represents exhalation of a mixture of dead space gases and alveolar gases. The **C – D** segment represents the alveolar plateau, characterized by exhalation of mostly alveolar gas. Point **D** is the end-tidal (EtCO₂) value that is recorded and displayed by the monitor, (peak concentration of CO₂ occurring at the end of expiration). The **D – E** segment (Inspiratory Downstroke), a sharp fall, reflects the inhalation of gases that are CO₂ – free (room air or supplemental oxygen). Alterations of the normal capnograph or EtCO₂ values are the result of changes in metabolism, circulation, ventilation, or equipment function.

A normal range for EtCO₂ is **35 – 45 mmHg**, similar to the range of CO₂ in arterial blood.

Normal Waveform:

Normal Capnography Waveform





EMS System for Metropolitan Oklahoma City and Tulsa 2022 Medical Control Board Treatment Protocols

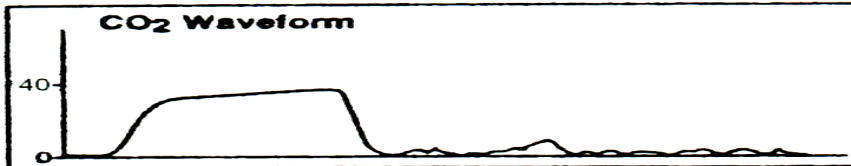


Approved 9/8/21, Effective 1/17/22, replaces all prior versions

PROTOCOL 3H: Waveform capnography – Adult & Pediatric, cont.

Abnormal Waveforms:

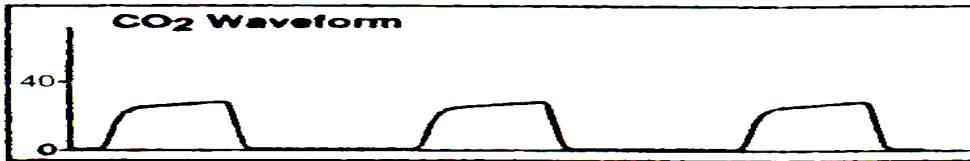
Sudden loss of ETCO₂ to zero or near zero:



Possible Causes:

1. Endotracheal tube in esophagus.
2. Apnea.
3. Endotracheal tube or supraglottic not connected to capnography detector.
4. Total obstruction/mucus plugging.
5. Capnography malfunction - if abnormal waveform persists with change in capnography adaptor, the endotracheal tube or supraglottic MUST be withdrawn and intubation or supraglottic placement reattempted.

Sustained low ETCO₂ with good alveolar plateau:



Possible Causes:

1. Hyperventilation (due to underlying illness/injury or excessive assisted ventilations).
2. Hypothermia (Decrease in Metabolism).

Sustained low ETCO₂ without alveolar plateau:



Possible causes:

1. Bronchospasm of asthma or COPD exacerbation.
2. Incomplete obstruction/mucus plugging.



EMS System for Metropolitan Oklahoma City and Tulsa 2022 Medical Control Board Treatment Protocols

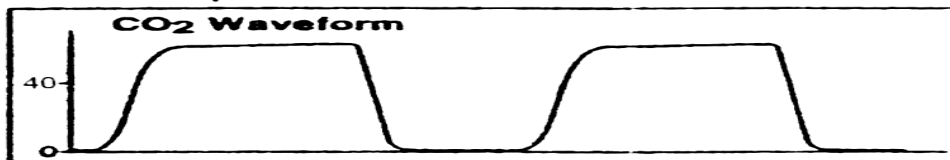


Approved 9/8/21, Effective 1/17/22, replaces all prior versions

PROTOCOL 3H: Waveform capnography – Adult & Pediatric, cont.

Abnormal Waveforms:


Elevated $ETCO_2$ with good alveolar plateau:



Possible causes:

1. Hypoventilation (due to underlying illness/injury or inadequate assisted ventilations).
2. Hyperthermia, pain, shivering (Increase in Metabolism).


Gradually increasing $ETCO_2$:



Possible causes:

1. Hypoventilation (due to underlying illness/injury or inadequate assisted ventilations).
2. Rising body temperature, increasing pain (Increasing Metabolism).

Exponential decrease in $ETCO_2$:



Possible causes:

1. Cardiopulmonary arrest.
2. Pulmonary embolism.
3. Sudden hypotension, massive blood loss, cardiopulmonary bypass.



EMS System for Metropolitan Oklahoma City and Tulsa 2022 Medical Control Board Treatment Protocols




Approved 9/8/21, Effective 1/17/22, replaces all prior versions

PROTOCOL 3H: Waveform capnography – Adult & Pediatric, cont.


Abnormal Waveforms:

Cardiogenic oscillations:



Cardiogenic oscillations are caused by changes in thoracic volume secondary to expansion and contraction of the myocardium with each heartbeat. They are usually seen in patients with small tidal volumes and slow respiratory rates, and are of little physiologic consequence.

Spontaneous breathing during mechanical ventilation:



Spontaneous breathing efforts may be evident on the CO2 waveform display. The patient on the top demonstrates poorer quality spontaneous breathing effort than the patient on the bottom.



EMS System for Metropolitan Oklahoma City and Tulsa 2022 Medical Control Board Treatment Protocols



Approved 9/8/21, Effective 1/17/22, replaces all prior versions

PROTOCOL 3H: Waveform capnography – Adult & Pediatric, cont.

Troubleshooting Tips for EtCO₂ monitoring:

Observation/Message	Possible Cause	Corrective Action
ALARM APNEA	No breath has been detected for 30 seconds since last valid breath	Check the patient, then ventilation equipment for leaks/disconnected tubing
CO₂ FILTERLINE OFF	FilterLine [®] , or any other CO ₂ accessories disconnected or not securely connected to the LifePak [®] EtCO ₂ connector	Connect FilterLine [®] , or any other CO ₂ accessories, to input connector or tighten connection
CO₂ FILTERLINE BLOCKAGE	FilterLine [®] is twisted or clogged. The message appears after 30 seconds of unsuccessful purging Airway Adapter clogged	Check the FilterLine [®] and if necessary replace it Check the Airway Adapter and necessary, replace it
CO₂ FILTERLINE PURGING	FilterLine [®] tube twisted or clogged with water	Check the FilterLine [®] and if necessary, untwist or reconnect it
EtCO₂ values erratic	A leak in the tubing Assisted ventilated patient breaths spontaneously	Check for connection leaks and line leaks to patient and correct if necessary
EtCO₂ values are consistently higher or lower than expected	Physiological cause Ventilator/Assisted ventilation error	Check patient (pulse?) Check ventilator &/or assisted ventilation rate Adjust EtCO ₂ scale to 0-20mmHg to reflect lower than anticipated value Print 6 second strip for verification of waveform
XXX appears in place of EtCO₂ value	CO ₂ module not calibrated successfully CO ₂ module failed	Notify appropriate supervisor/materials agent of critical equipment failure