



# EMS System for Metropolitan Oklahoma City and Tulsa 2021 Medical Control Board Treatment Protocols



Approved 9/9/20, Effective 1/15/21, replaces all prior versions

## 2I – CRICOTHYROTOMY ADULT

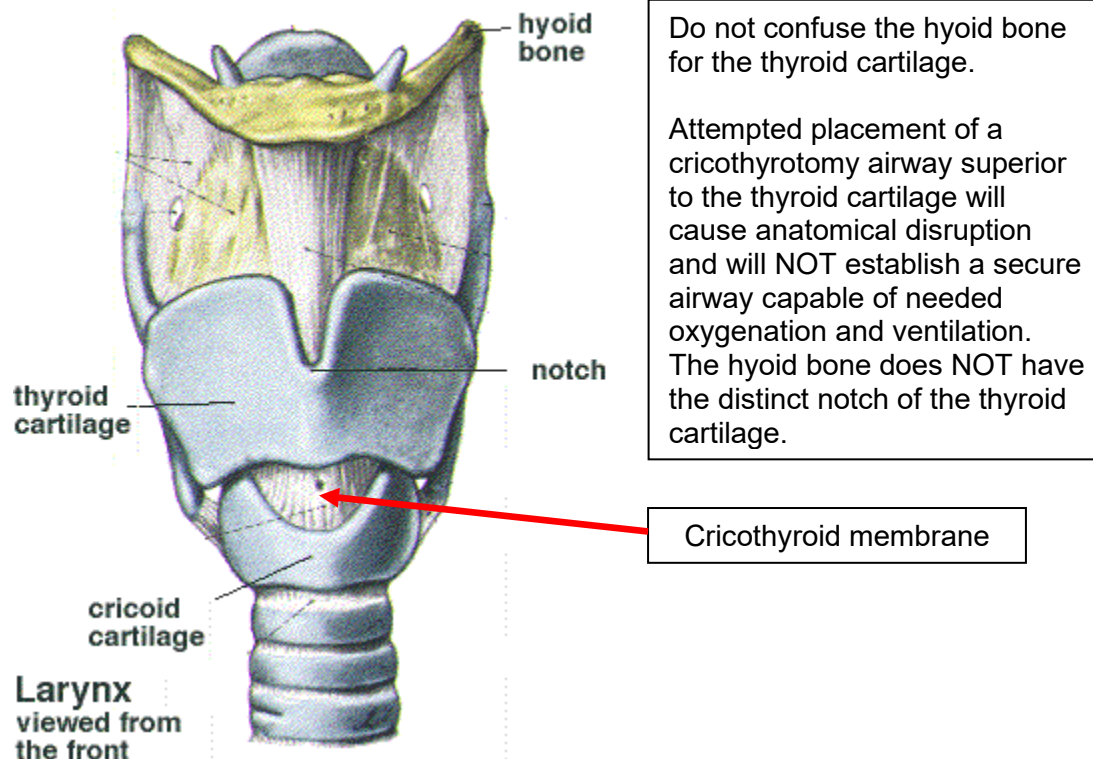
PARAMEDIC

### Indications:

1. Upper airway obstruction (eg. facial or neck trauma occluding airway patency, foreign body unable to be removed, angioedema) and inability to adequately oxygenate and ventilate using less invasive methods.

### Contraindications:

1. Ability to oxygenate and ventilate using less invasive methods.
2. Infant and younger pediatrics – airway anatomical size not conducive to successful cricothyrotomy in EMS care. Contact OLMC for direction in these ages.
3. Older pediatrics – airway anatomical size MAY not be conducive to successful cricothyrotomy in EMS care. Contact OLMC for direction in these ages.
4. Suspected fractured larynx and/or cricoid cartilage.
5. Suspected tracheal transection with retraction of the trachea into the chest.
6. Inability to find anatomical landmarks





## EMS System for Metropolitan Oklahoma City and Tulsa 2021 Medical Control Board Treatment Protocols

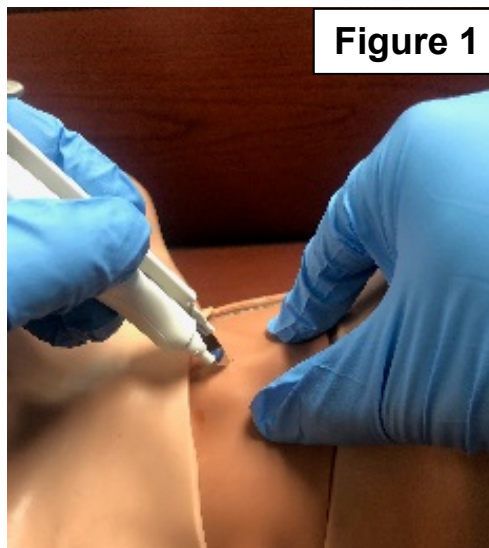


Approved 9/9/20, Effective 1/15/21, replaces all prior versions

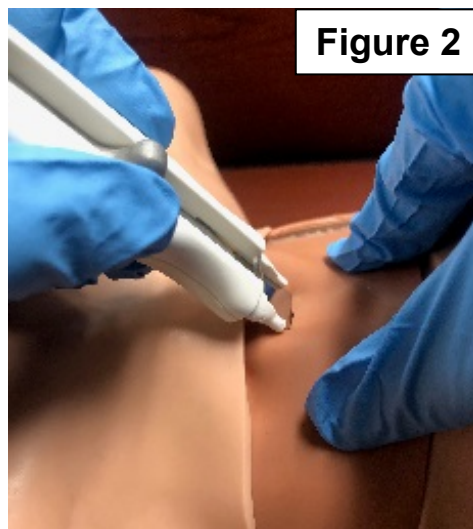
### PROTOCOL 2I: Emergency Cricothyrotomy – Adult, cont.

#### Non-Surgical Technique (Control-Cric™):

- A. Position patient supine and identify the cricothyroid membrane.
- B. Stabilize the thyroid cartilage with the non-dominant hand (illustration shows the right hand as non-dominant). The dominant hand rests on the sternum, holding the device, with the scalpel oriented horizontal, across the neck at the cricothyroid membrane (illustration shows the left hand as dominant). (Figure 1)



- C. Inserting the scalpel to its depth safety hub, make a horizontal incision through both the skin and the underlying cricothyroid membrane. (Figure 2)





## EMS System for Metropolitan Oklahoma City and Tulsa 2021 Medical Control Board Treatment Protocols

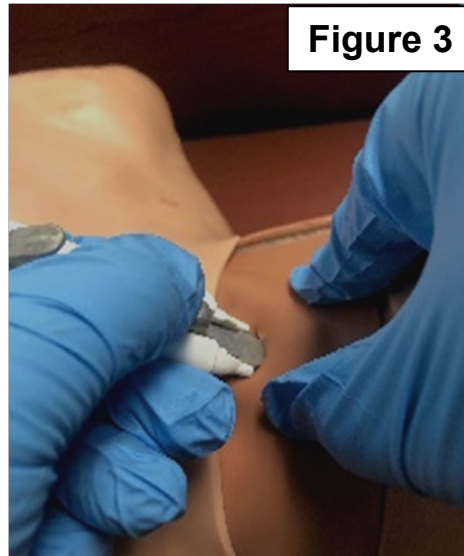


Approved 9/9/20, Effective 1/15/21, replaces all prior versions

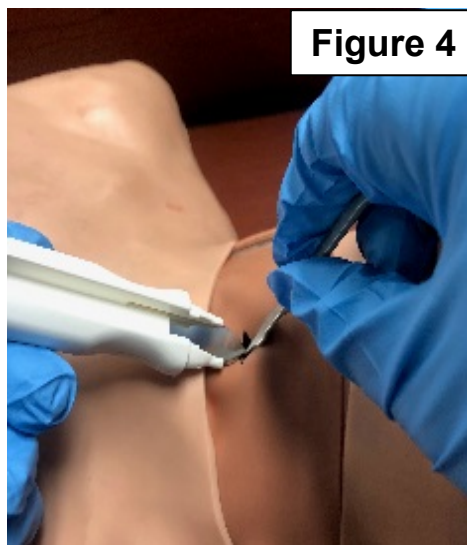
### PROTOCOL 2I: Emergency Cricothyrotomy – Adult, cont.

#### Non-Surgical Technique (Control-Cric™), cont:

- D. Slide the included tracheal hook down the handle with the thumb placed at the knob, advancing the tip of the hook into the incision made in Step C/Figure 2. (Figure 3)



- E. Free the tracheal hook from the handle by sliding it fully down the handle and transfer control of the hook to the non-dominant hand. The tracheal hook should now be able to stabilize movement of the trachea as it is pulled in a controlled force and manner, with the hook under the inferior edge of the thyroid cartilage. (Figure 4)





## EMS System for Metropolitan Oklahoma City and Tulsa 2021 Medical Control Board Treatment Protocols

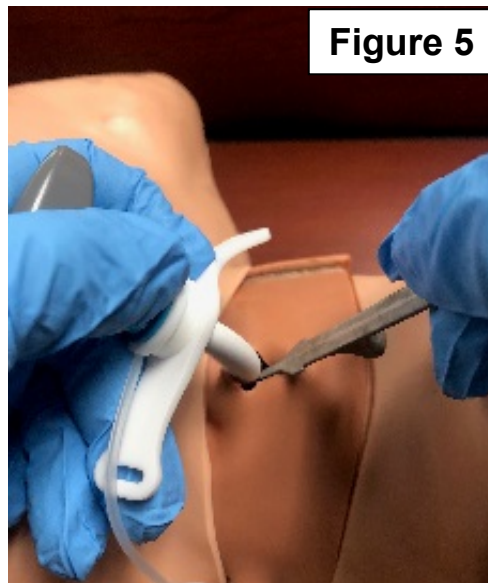

Approved 9/9/20, Effective 1/15/21, replaces all prior versions

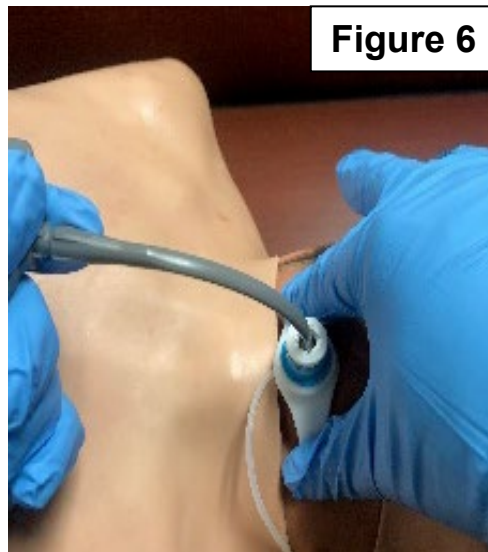
### PROTOCOL 2I: Emergency Cricothyrotomy – Adult, cont.

#### Non-Surgical Technique (Control-Cric™), cont:

- F. Insert the Cric-Key™ through the cricothyroid membrane incision. Confirm placement by moving the Cric-Key™ introducer along the anterior wall of the trachea to feel for the tracheal rings as partial confirmation of correct placement. (Figure 5)



- G. Remove the Cric-Key™ introducer. (Figure 6) Inflate the cuff until resistance is met. Confirm placement with continuous waveform capnography. See also Protocol 3H: Waveform Capnography – Adult & Pediatric.





## EMS System for Metropolitan Oklahoma City and Tulsa 2021 Medical Control Board Treatment Protocols

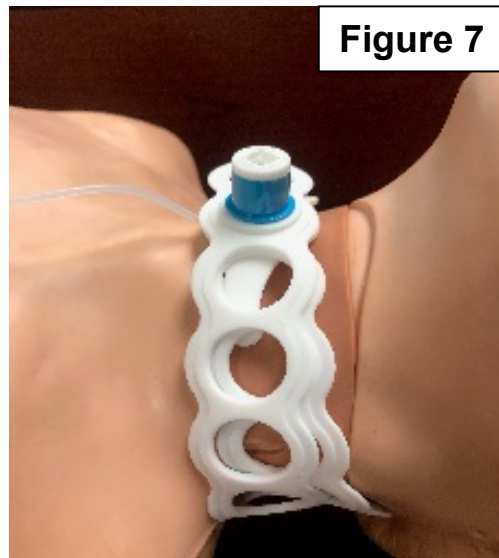


Approved 9/9/20, Effective 1/15/21, replaces all prior versions

### **PROTOCOL 2I: Emergency Cricothyrotomy – Adult, cont.**

#### Non-Surgical Technique (Control-Cric™), cont:

G. Secure the cricothyrotomy airway with the included stabilizing strap. (Figure 7)



#### Surgical Technique (6.0 endotracheal tube and tracheal hook):

- A. Establish adequate space and lighting. Do not attempt cricothyrotomy in poorly visualized conditions.
- B. If rapidly available, clean anterior neck with Chloraprep®, Betadine®, or alcohol wipe.
- C. Definitively locate the following landmarks: thyroid cartilage (“Adam’s apple”) and cricoid cartilage. The cricothyroid membrane lies between these cartilages.
- D. Using the non-dominant hand, spread the overlying skin taut with the thumb and fingers, and slightly depress the skin over the cricothyroid membrane with the index finger to mark the site of cricothyrotomy. Do not release the non-dominant hand from the neck until the procedure is complete! Once the anatomy is found and defined, avoid movement of the anatomy to promote proper cricothyrotomy airway placement.
- E. Stabilization of the anatomy requires assistance from a second EMS professional, preferably licensed as a paramedic as well.
- F. Ask second EMS professional to aspirate all air from the endotracheal tube cuff.



## EMS System for Metropolitan Oklahoma City and Tulsa 2021 Medical Control Board Treatment Protocols



Approved 9/9/20, Effective 1/15/21, replaces all prior versions

### **PROTOCOL 2I: Emergency Cricothyrotomy – Adult, cont.**

#### Surgical Technique, cont.:

- G. Using a sterile scalpel, make a vertical incision in the mid-line of the neck extending from just above the lower edge of the thyroid cartilage to the middle of the cricoid cartilage. Make the depth of this incision sufficient to extend through the skin and fatty tissue underneath.
- H. Using sterile hemostats, spread the incision open horizontally to expose the cricothyroid membrane. Instruct the second EMS professional to hold the hemostats in this position.
- I. Using the same scalpel as in Step G, now make a short horizontal incision in the middle of the cricothyroid membrane. There is a small artery running vertically on each side of the cricothyroid membrane. Keeping the horizontal incision less than ½ inch (approx. 1 cm) will decrease bleeding that may occur.
- J. Pass the 6.0 mm endotracheal tube through the horizontal incision in the cricothyroid membrane, angling the tube inferior and posterior along the tracheal anatomy. A “washboard” sensation may be felt as the tube slides along the tracheal wall. Avoid excessive pressure in placing the endotracheal tube, but a moderate degree may be required to first pass the endotracheal tube through the cricothyroid membrane. If significant resistance is encountered (without suspicion of lower respiratory tract foreign body), the hemostats used in Step H may be used to spread the cricothyroid membrane incision vertically while the endotracheal tube is passed through it and/or use of the tracheal hook may better stabilize the anatomy to overcome resistance to airway passage.
- K. Inflate the endotracheal cuff and verify airway placement per Protocol 2J – Confirmation of Artificial Airway Placement.
- L. Secure the airway using a cloth tie or commercial endotracheal tube restraint while continuing oxygenation and ventilation. Artificial ventilation will generally be easier if the endotracheal tube is cut to a shorter length. Be careful to cut the upper aspect of the endotracheal tube above the insertion site of the cuff inflation portal to avoid irreversible cuff deflation.



## EMS System for Metropolitan Oklahoma City and Tulsa 2021 Medical Control Board Treatment Protocols



Approved 9/9/20, Effective 1/15/21, replaces all prior versions

### **PROTOCOL 2I: Emergency Cricothyrotomy – Adult, cont.**

#### Modified Non-Surgical Technique (Control-Cric™):

In patients with neck edema, subcutaneous air, or fat/obesity preventing necessary tactile identification of anatomical landmarks to perform standard non-surgical cricothyrotomy, utilize the following modification:

- A. Using the included scalpel, make a single, vertical, mid-line incision in the skin overlying the area that is estimated to contain the thyroid cartilage, cricothyroid membrane, and cricoid cartilage. When making the incision, make an incision approximately 2 inches (5 cm) in length and deep enough that the subcutaneous fat can be visualized. Using a gloved index finger palpate the structures through the incision and when identified, proceed as per standard non-surgical cricothyrotomy.