



EMS System for Metropolitan Oklahoma City and Tulsa 2022 Medical Control Board Treatment Protocols



Approved 9/8/21, Effective 1/17/22, replaces all prior versions

2F – ORAL INTUBATION ADULT

EMT-INTERMEDIATE 85

ADVANCED EMT

PARAMEDIC

Indications:

1. Hypoxia and/or hypoventilation refractory to non-invasive airway/respiratory management.
2. Airway protection to minimize aspiration in the setting of sustained altered mental status with a Glasgow Coma Scale Score <8.
3. Impending airway edema in the setting of respiratory tract burns or anaphylaxis.

Contraindications:

1. A total of three unsuccessful oral and/or nasal intubation attempts in the above settings. An intubation attempt has occurred when the tip of the endotracheal tube is advanced beyond the gum line or into a nostril. Attempts are counted per patient not per intubator.
2. Waveform capnography not immediately available.

Technique:

1. Throughout the period pre-, during, post-intubation the patient must be continually monitored for hypoxia, bradycardia, or hypotension. Corrective measures, including BVM oxygenation should take priority over continuing the current intubation attempts.
2. In pulsatile (non-cardiac arrest) patients, provide supplemental oxygenation throughout the intubation process with nasal cannula oxygen delivery at 15 lpm flow. While this flow rate is much higher than typical nasal cannula oxygen flow rates, the additional force of 15 lpm will help to reduce intra-intubation oxygen desaturation/hypoxia.
3. Walk the laryngoscope down the tongue to avoid placing the laryngoscope in the esophagus.
4. If unable to lift the mandible with the laryngoscope, place your left forearm on the pt's head for leverage.
5. If the vocal cords are poorly visualized in any patient, manipulate the thyroid cartilage with your right hand until appropriate visualization is achieved. Have a colleague hold the thyroid cartilage in this place while you finish intubating. This technique is referred to as "bimanual laryngoscopy" and works much more reliably than cricoid pressure.
6. If the vocal cords are still poorly visualized in obese patients without suspected spinal injury, elevate their head/neck/shoulders. Place blankets or pillows under the head/neck/shoulders until the patient's chin or nose is level with the chest.



EMS System for Metropolitan Oklahoma City and Tulsa 2022 Medical Control Board Treatment Protocols



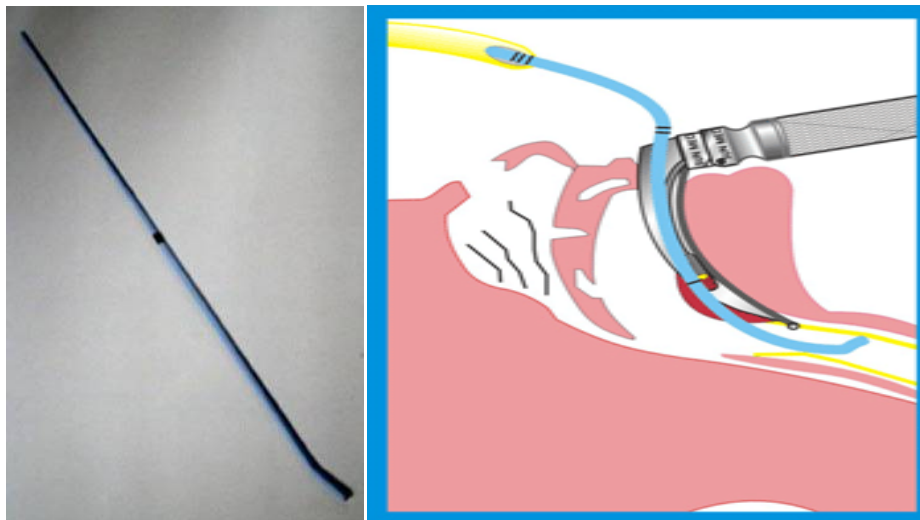
Approved 9/8/21, Effective 1/17/22, replaces all prior versions

PROTOCOL 2F: Oral Intubation – Adult, cont.

7. If ambient light inhibits visualization of the larynx, block this light by any means possible, including a blanket stretched over your head and the patient's head and neck.
8. In adult patients of appropriate size, strong preference is given for using the 8.0 mm endotracheal tube for orotracheal intubation. Use of this sized tube enables inpatient pulmonary care unable to be performed with smaller sized tubes.
9. It is strongly recommended the Flex-Guide™ introducer be used during any second intubation attempt.
10. It is required the Flex-Guide™ introducer be used during the third intubation attempt.

The Flex-Guide™ Introducer (also known as the Gum Elastic Bougie):

The Flex-Guide™ Introducer is a single patient use, semi-rigid plastic rod with an angled tip, promoting glottic passage when the vocal cords are incompletely visible during laryngoscopy. A 1 cm wide black band is located along the Flex-Guide™ to help determine correct placement depth. The Flex-Guide™ shape and elasticity allow the intubator to feel a “washboard” sensation as the anteriorly-angled tip is advanced down the tracheal rings. Failure to feel a “washboard” sensation indicates inadvertent esophageal placement and the Flex-Guide™ must be fully withdrawn before reattempting placement. The Flex-Guide™ length allows it to be advanced to the carina where resistance is met, also a means of confirming tracheal rather than esophageal placement. Avoid storing the Flex-Guide™ coiled, as it works best in these regards when it is straight. The Flex-Guide™ is contraindicated in patients ≤ 16 years of age.



Flex-Guide™ Introducer Technique:

1. Advance the angled tip facing anteriorly, with continual visualization by laryngoscopy. Anytime resistance is met, stop advancing and reassess placement - forceful passage can result in perforation of soft tissues.
2. Stabilize the Flex-Guide™ when in place, while maintaining laryngoscopy



EMS System for Metropolitan Oklahoma City and Tulsa 2022 Medical Control Board Treatment Protocols



Approved 9/8/21, Effective 1/17/22, replaces all prior versions

PROTOCOL 2F: Oral Intubation – Adult, cont.

3. Direct a colleague to slide the endotracheal tube over the Flex-Guide™. He or she stabilizes the proximal end of the Flex-Guide™ as it emerges from the sliding endotracheal tube.
4. Take control of the endotracheal tube, sliding it down the Flex-Guide™ length, while being careful to avoid Flex-Guide™ migration. Once the endotracheal tube has passed to an appropriate estimated endotracheal depth, stabilize it while your colleague withdraws the Flex-Guide™ prior to laryngoscope removal

Confirmation of Oral Endotracheal Placement:

The following sequence is to be used (and its use documented) to verify and maintain correct oral endotracheal placement without fail:

1. **Visualization of endotracheal tube passage between the vocal cords.**
2. **Detection of End-tidal carbon dioxide.** End-tidal carbon dioxide (EtCO₂) detection shall be confirmed within 60 seconds of endotracheal tube placement. The capnography adaptor is to be placed at the bag-valve device-endotracheal tube interface for the first ventilation. The normal waveform indicating correct endotracheal placement reflects a rapid upstroke with the beginning of exhalation, the exhalation plateau ending at the point of EtCO₂ measurement, and a rapid downstroke with the beginning of inhalation. Any waveform that does not show rhythmic rise and fall correlating with assisted ventilations indicates incorrect tube placement and the tube must be withdrawn. **To be perfectly clear, the use of an endotracheal tube for ongoing oxygenation and ventilation is dependent upon continuously measurable capnography waveforms.** See Protocol 3H-Capnography for discussion of EtCO₂ values.
3. **Auscultation. Auscultate the epigastrium.** If epigastric sounds are heard, intubation is to be reattempted. The endotracheal tube placed in the esophagus may be left in place, at the intubator's discretion, until another endotracheal tube is correctly placed and verified. If no epigastric sounds are heard, proceed to **auscultation of the thorax bilaterally**. Breath sounds are best auscultated in the anterior to mid axillary lines. If breath sounds are present on the right and absent on the left, this suggests a right main stem intubation. Withdraw the endotracheal tube 1cm and repeat auscultation. If necessary, the tube may be withdrawn an additional 1-2cm.
4. **Assessment of physiologic changes.** These include equal rise and fall of the chest, condensation in the endotracheal tube on exhalation, improvement in the patient's color, and improvement in the patient's respiratory distress or failure.



EMS System for Metropolitan Oklahoma City and Tulsa 2022 Medical Control Board Treatment Protocols



Approved 9/8/21, Effective 1/17/22, replaces all prior versions

PROTOCOL 2F: Oral Intubation – Adult, cont.

5. Secure the endotracheal tube with a tube holder and place a cervical collar.

When intubated patients are moved during EMS care, waveform capnography must be rechecked for any change. If the waveform continues to show a normal pattern of rapid upstroke with exhalation, exhalation plateau, and rapid downstroke with inhalation, no further repeat confirmation is required. If at any time, the capnography waveform is abnormal, steps 2-5 must be rechecked and documented. If at any time during patient care there is doubt as to correct endotracheal placement of intubation, you must either re-verify by this sequence or reattempt correct endotracheal placement. While the intubator may delegate confirmation steps to his/her colleagues, he or she is ultimately responsible to ensure that a complete confirmation sequence is performed. If the intubator accompanies the patient to the hospital, he or she remains ultimately responsible for ongoing endotracheal tube placement confirmation. If the intubator does not accompany the patient to the hospital by ambulance or helicopter ambulance transport, the primary transporting/treating paramedic or RN assumes ultimate responsibility for ongoing endotracheal tube placement confirmation.

Post-Endotracheal Intubation Additional Care:

Place a nasogastric or orogastric tube to intermittent suction in order to alleviate gastric air/distension. This will improve oxygenation/ventilation and decrease risk of aspiration.