



EMS System for Metropolitan Oklahoma City and Tulsa 2022 Medical Control Board Treatment Protocols



Approved 9/8/21, Effective 1/17/22, replaces all prior versions

10E – NEEDLE THORACOSTOMY – TENSION PNEUMOTHORAX DECOMPRESSION ADULT & PEDIATRIC

PARAMEDIC

Indications:

Suspected tension pneumothorax

Clinical signs of tension pneumothorax:

Increasing respiratory insufficiency in a susceptible patient:

1. Spontaneous pneumothorax
2. CPR with appearance of PEA, increased difficulty bagging patient
3. Sucking chest wound which has been covered and which has not responded to removal of the seal/dressing
4. Chest trauma with suspected pneumothorax AND

Adult systolic blood pressure less than 100 mmHg (or pediatric systolic blood pressure less than $70 + (2 \times \text{age in years})$ mmHg **AND**

Three or more of the following:

1. "Air Hunger"
2. Cyanosis
3. Decreased breath sounds on affected side(s)
4. Jugular venous distension
5. Tracheal shift away from affected side – extremely late sign – do not wait as indication for needle thoracostomy if other signs are developing

Etiologies of tension pneumothorax include:

1. Trauma (blunt or penetrating) - disruption of either visceral or parietal pleura; often associated with rib fractures (rib fractures not necessary for tension pneumothorax to occur)
2. Barotrauma secondary to positive-pressure ventilation, especially when using high amounts of positive end-expiratory pressure (PEEP)
3. Unsuccessful attempts to convert an open pneumothorax to a simple pneumothorax in which the occlusive dressing functions as a 1-way valve
4. Chest compressions during cardiopulmonary resuscitation

Contraindications:

None absolute. Do not place a needle thoracostomy through an area of suspected cellulitis, using instead an alternative site – 5th intercostal space mid-axillary line.



EMS System for Metropolitan Oklahoma City and Tulsa 2022 Medical Control Board Treatment Protocols



Approved 9/8/21, Effective 1/17/22, replaces all prior versions

PROTOCOL 10E: Needle Thoracostomy -Tension Pneumothorax Decompression - Adult & Pediatric, cont.

Precautions:

1. A SIMPLE pneumothorax causes some degree of respiratory distress and chest pain, and MAY be associated with decreased or absent breath sounds on the side of the collapse and with subcutaneous air if the cause is traumatic. TENSION pneumothorax is associated with progressive respiratory distress, dropping BP, "drum-like" hyperexpanded chest, distended neck veins, and patient deterioration. Tracheal shift may be present but is a late sign and needle decompression should be accomplished before waiting for the appearance of tracheal shift.
2. Pneumothorax rarely presents with tension on initial assessment. Be particularly suspicious with deterioration during transport, and with patients requiring assisted ventilation.
3. In patients who are being ventilated by bag-valve mask or ventilator, caution should be exercised when performing needle decompression. If the presumptive diagnosis of a tension pneumothorax is incorrect, the insertion of the needle may create a pneumothorax, which may be converted into a tension pneumothorax by positive-pressure ventilation.
4. If a previously covered sucking chest wound is present, remove the seal and allow chest pressures to equilibrate. No further treatment is often necessary.

Technique:

- A. Expose the entire chest.
- B. Locate landmark on affected side(s) second intercostal space just superior to third rib, (Figure 1 illustrates the right side of the chest as the affected side).
- C. Clean area of insertion with Chloraprep®, Betadine®, or alcohol prep.
- D. Attach 10 mL or larger syringe to a 15 gauge pneumothorax catheter or a 14 gauge angiocatheter. If using an angiocatheter, the length of the needle should be at least 3.25 inches to promote decompression of the pleural space. Thick chest wall musculature may prevent entry into the pleural space if using a shorter needle.
- E. Decisively locate the second or third intercostal space in the mid-clavicular line.
- F. Insert the needle through the skin at near or at 90 degrees and advance until tip hits the top of the rib below the intercostal space. Continue to advance angling over the top of the rib margin – advance just over the lower rib avoid the neurovascular bundle running horizontally along the lower border of the upper rib.
- G. Advance needle tip into the pleural space. A slight “pop” is usually felt when the needle pierces the outside pleural membrane, or parietal pleura.

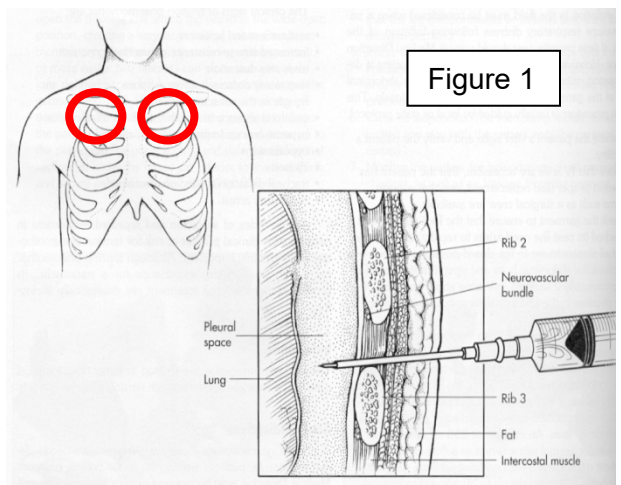


Figure 1



EMS System for Metropolitan Oklahoma City and Tulsa 2022 Medical Control Board Treatment Protocols



Approved 9/8/21, Effective 1/17/22, replaces all prior versions

PROTOCOL 10E: Needle Thoracostomy - Tension Pneumothorax Decompression - Adult & Pediatric, cont.

Technique, cont.:

- H. When tension is present, syringe plunger will typically dislodge back out of syringe, or an immediate hiss of air escaping will be heard.
- I. Remove the syringe and needle and leave the catheter in the pleural space.
- J. If recurrent decompression of the patient occurs related to suspected redevelopment of tension pneumothorax, repeat the procedure next to the previously successful needle thoracostomy site.

Complications:

1. Creation of pneumothorax if none existed previously. This is an unfortunate occurrence if needle thoracostomy is done too aggressively. Do not hesitate to relieve a strongly suspected tension pneumothorax but perform an accurate assessment to validate the suspicion of tension pneumothorax.
2. Laceration of lung, which is rare, can cause significant pulmonary injury. Avoid excessive length needles.
3. Hemothorax from vascular injury. Avoid needle thoracostomy medial to the mid-clavicular line. Avoid needle thoracostomy just inferior to a rib, where the intercostal vessels run underneath the rib margin.
4. Infection. Minimize risk by clean insertion site and maintaining aseptic technique, using sterile catheters/needles.

Note:

Studies show that needle thoracostomy in the 5th or 6th intercostal space at the mid-axillary line is effective in the release of tension pneumothorax. Utilize this location if the traditional sites of the 2nd or 3rd intercostal space at the mid-clavicular line do not improve the respiratory or hemodynamic conditions of a patient with a strongly suspected tension pneumothorax, especially if using shorter angiocatheters. The chest wall musculature is thinner in this alternate location.