



## EMS System for Metropolitan Oklahoma City and Tulsa 2024 Medical Control Board Treatment Protocols



Approved 11/08/23, Effective 1/15/24, replaces all prior versions

### 10E – NEEDLE THORACOSTOMY – TENSION PNEUMOTHORAX DECOMPRESSION ADULT & PEDIATRIC

#### PARAMEDIC

#### Indications:

Suspected tension pneumothorax

#### Clinical signs of tension pneumothorax:

Increasing respiratory insufficiency in a susceptible patient:

1. Spontaneous pneumothorax
2. CPR with appearance of PEA, increased difficulty bagging patient
3. Sucking chest wound which has been covered and which has not responded to removal of the seal/dressing
4. Chest trauma with suspected pneumothorax AND

Adult systolic blood pressure less than 100 mmHg (or pediatric systolic blood pressure less than  $70 + (2 \times \text{age in years})$  mmHg **AND**

Three or more of the following:

1. "Air Hunger"
2. Cyanosis
3. Decreased breath sounds on affected side(s)
4. Jugular venous distension
5. Tracheal shift away from affected side – extremely late sign – do not wait as indication for needle thoracostomy if other signs are developing

Etiologies of tension pneumothorax include:

1. Trauma (blunt or penetrating) - disruption of either visceral or parietal pleura; often associated with rib fractures (rib fractures not necessary for tension pneumothorax to occur)
2. Barotrauma secondary to positive-pressure ventilation, especially when using high amounts of positive end-expiratory pressure (PEEP)
3. Unsuccessful attempts to convert an open pneumothorax to a simple pneumothorax in which the occlusive dressing functions as a 1-way valve
4. Chest compressions during cardiopulmonary resuscitation

#### Contraindications:

No absolute contraindications. Do not place a needle thoracostomy through an area of suspected cellulitis, using instead an approved alternative site.



## EMS System for Metropolitan Oklahoma City and Tulsa 2024 Medical Control Board Treatment Protocols



Approved 11/08/23, Effective 1/15/24, replaces all prior versions

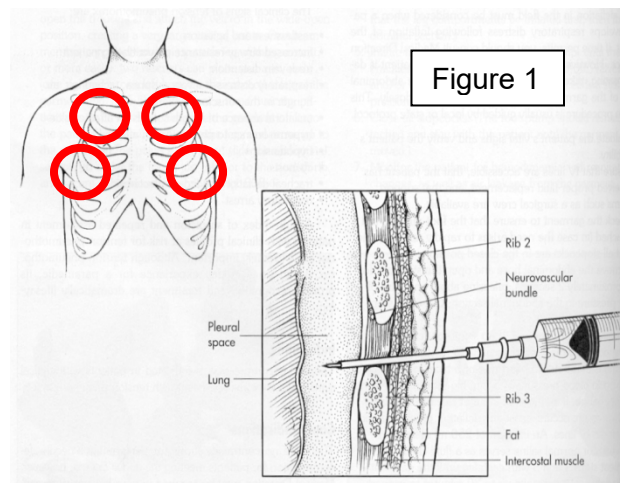
### PROTOCOL 10E: Needle Thoracostomy -Tension Pneumothorax Decompression - Adult & Pediatric, cont.

#### Precautions:

1. A SIMPLE pneumothorax causes some degree of respiratory distress and chest pain, and MAY be associated with decreased or absent breath sounds on the side of the collapse and with subcutaneous air if the cause is traumatic. TENSION pneumothorax is associated with progressive respiratory distress, dropping BP, "drum-like" hyperexpanded chest, distended neck veins, and patient deterioration. Tracheal shift may be present but is a late sign and needle decompression should be accomplished before waiting for the appearance of tracheal shift.
2. Pneumothorax rarely presents with tension on initial assessment. Be particularly suspicious with deterioration during transport, and with patients requiring assisted ventilation.
3. In patients who are being ventilated by bag-valve mask or ventilator, caution should be exercised when performing needle decompression. If the presumptive diagnosis of a tension pneumothorax is incorrect, the insertion of the needle may create a pneumothorax, which may be converted into a tension pneumothorax by positive-pressure ventilation.
4. If a previously covered sucking chest wound is present, remove the seal and allow chest pressures to equilibrate. This should allow air to escape relieving the tension pneumothorax.

#### Technique:

- A. Expose the entire chest.
- B. Locate landmark on affected side(s), (figure 1)
  - a. Adult: fourth or fifth intercostal space-anterior axillary just superior to the lower rib
  - b. Pediatric: second intercostal space-midclavicular just superior to third rib
- C. Clean area of insertion with ChlorPrep®, Betadine®, or alcohol prep.
- D. Attach 10 mL or larger syringe to a 15 gauge Cook pneumothorax catheter or use a 10-gauge SPEAR catheter (no syringe).
- E. Decisively locate the insertion point.
- F. Insert the needle at 90 degrees through the skin and advance until tip of the needle hits the top of the rib below the intercostal space penetrated by the needle. Continue to advance angling over the top of the rib to avoid the neurovascular bundle running horizontally under the rib above the intercostal space is penetrated.
- G. Advance of the needle tip into the pleural space. A slight "pop" is usually felt when the needle pierces the outside pleural membrane, or parietal pleura.





## EMS System for Metropolitan Oklahoma City and Tulsa 2024 Medical Control Board Treatment Protocols



Approved 11/08/23, Effective 1/15/24, replaces all prior versions

### **PROTOCOL 10E: Needle Thoracostomy - Tension Pneumothorax Decompression - Adult & Pediatric, cont.**

#### Technique, cont.:

- H. When tension is present, syringe plunger will typically dislodge back out of syringe, or an immediate hiss of air escaping will be heard.
- I. If using the 10-gauge SPEAR catheter the plastic catheter should be separated after signs of proper placement. This is achieved after the needle has been inserted to an estimated depth of:
  - a. <1 y.o. = ~½ cm past the rib
  - b. >1 y.o. – <12 y.o. = ~1- 3 cm past the rib
  - c. 12 y.o - Adult = ~3 cm past the rib
- J. Remove the syringe and needle and leave the catheter in the pleural space.
- K. If using the 10-gauge SPEAR catheter remove the one-way valve from the needle hub and attach it to the catheter hub.
- L. If recurrent decompression of the patient occurs related to suspected redevelopment of tension pneumothorax, repeat the procedure next to the previously successful needle thoracostomy site.

#### Complications:

1. Creation of pneumothorax if none existed previously. This is an unfortunate occurrence if needle thoracostomy is done too aggressively. Do not hesitate to relieve a strongly suspected tension pneumothorax but perform an accurate assessment to validate the suspicion of tension pneumothorax.
2. Laceration of lung, which is rare, can cause significant pulmonary injury. Avoid excessive length needles.
3. Hemothorax from vascular injury. Avoid needle thoracostomy medial to the mid-clavicular line. Avoid needle thoracostomy just inferior to a rib, where the intercostal vessels run underneath the rib margin. Avoid needle thoracostomy inferior to the right 6<sup>th</sup> intercostal space to avoid the upper margin of the liver.
4. Infection. Minimize risk by clean insertion site and maintaining aseptic technique, using sterile catheters/needles.

#### Note:

Both the 2<sup>nd</sup> Intercostal space-midclavicular line and the 4<sup>th</sup> or 5<sup>th</sup> Intercostal space-anterior axillary line are effective in the release of tension pneumothorax. Utilize this alternate location if the preferred site does not improve the respiratory or hemodynamic conditions of a patient with a strongly suspected tension pneumothorax.